

NET


Neuroelectric Therapy Eliminates Xerostomia During Radiotherapy—A Case History

NATHALIE S. BOSWELL, MA

A patient receiving radiation therapy for squamous cell carcinoma of the right tonsillar area was given Neuroelectric Therapy (NET) immediately following each radiation treatment. The following adverse reactions to radiation were expected—irreversible xerostomia, temporary dysgeusia, throat pain, and possible mucositis and radiation dermatitis. Due to the NET treatments, all adverse reactions were either eliminated or reduced drastically. Xerostomia and dysgeusia were eliminated. The patient required no regimen of pain medication because NET reduced the level of pain each day after radiation; he showed no signs of mucositis or radiation dermatitis at any time. Follow-up for five months

post-radiation with periodic NET treatments regained near-normal salivation after each treatment.

Although radiation therapy has improved over the last thirty years and side-effects reduced, all patients undergoing radiation therapy of the tonsillar area experience some degree of mucositis and dysgeusia.^(1,2,3) Patients receiving radiation to the lateral pharyngeal areas are all subject to rapid and profound xerostomia.⁽³⁾ The following is a report of the use of Neuroelectric Stimulation in the elimination of these adverse conditions in a patient undergoing radiotherapy covering both lateral pharyngeal areas for squamous cell carcinoma of the right tonsillar area.



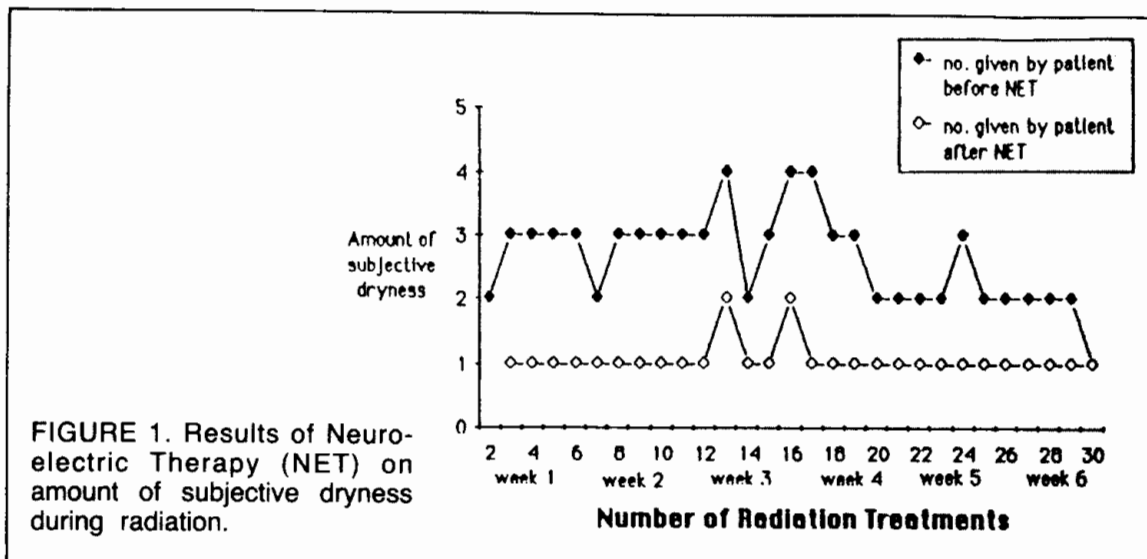


FIGURE 1. Results of Neuroelectric Therapy (NET) on amount of subjective dryness during radiation.

BACKGROUND INFORMATION

Neuroelectric therapy (NET) is a relatively new technique that has recently been used for treatment of pain, healing of bone and skin tissue, and some muscle degenerative processes, to name a few.^(4,5,6) The mechanism of action is as yet theoretical, but experimental evidence is accumulating which may explain how electromagnetic energy interacts with the cellular membrane.⁽⁴⁾

Electrical stimulation for the patient in this case study was provided by a pulse generator (Alpha-Stim 2000) with a frequency of 0.5 Hertz and an intensity of 50 to 500 microamperes, the duration of stimulation varying from 8 seconds to thirty minutes. The stimulation was administered by noninvasive electrodes in two stages: (1) specific sites on both auricles and (2) the radiation field area.

CASE REPORT

A 61-year-old male veteran seen at the Cleveland VA Medical Center received 6000 Rads during radiotherapy, covering both right and left pharyngeal areas, administered by a megavolt cobalt linear accelerator.

Diagnosed as having a T₂N₁M₀ squamous-cell carcinoma of the right tonsillar area, the patient was administered NET within four hours following each radiation treatment, beginning with his third radiation treatment. Teeth had been extracted before radiation due to poor prophylaxis.

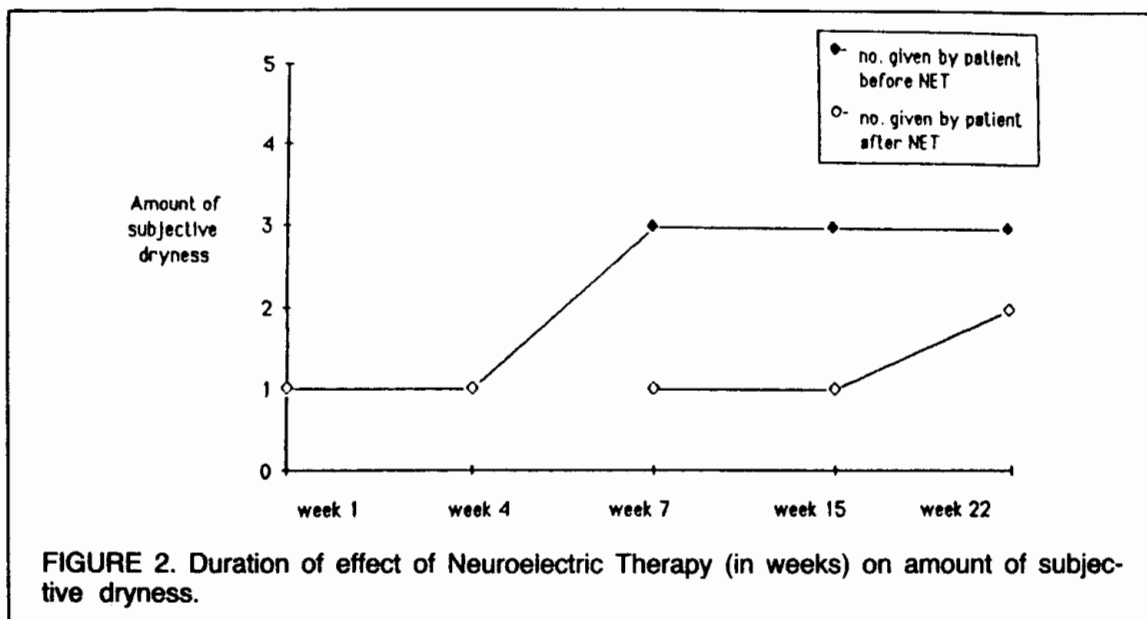
Prior to each NET treatment, the patient was asked to rate his dryness on a five-point scale:

1. Ample salivation present for normal feeling of tongue and throat. No difficulty swallowing.
2. Ample saliva, but beginning to feel like cotton.
3. Less saliva in the mouth; throat feels a little dry.
4. Very little saliva in the mouth; tongue and throat are dry. It is hard to swallow.
5. No saliva in the mouth; throat and tongue are very dry. I cannot swallow.

Immediately following each NET treatment, the patient again rated his dryness. After treatment, the patient exhibited no mucositis, radiation dermatitis, or dysgeusia. Even throat pain was eliminated with each NET treatment.

Figure 1 summarizes the results of the patient's NET treatments on his xerostomia. Before each treatment, the xerostomia remained stable at level 3 until the second week of radiation, then rose to level 4; it then decreased to level 2, and was normal on the last day.

After termination of the radiation-NET regimen, xerostomia was absent for one month (Figure 2). Within two months, the basic dryness level had increased to level 3. With further applications of NET, this level was reduced to a 1 or 2. For the last two months of follow-up, the patient reported an occasional level-5 dryness. This appeared about one-half hour after meals, or when he had to breathe through his mouth. However, within a period of one hour, the dryness decreased again to level 1.



DISCUSSION

Because all of the patient's salivary glands were included in the radiation fields, he was instructed that he would have irreversible xerostomia, and dysgeusia for from 20 to 60 days post-radiation. According to Figure 1, he began to lose resting secretion at the usual time (2 to 3 doses of 200 Rads) and, by the end of the second week, unstimulated saliva flow had fallen well below preradiation flow, also expected. Here the cumulative effects of NET⁽⁵⁾ began to show in that his xerostomia began to abate; by the termination of radiation, saliva flow was normal.

If follow-up could have been on a more regular basis, the possibilities are that his xerostomia could have been maintained at levels 1 or 2.

Because of the NET treatment, it is of interest to note that he had none of the expected severe adverse reactions to radiation therapy; this is highly unusual since some degree of xerostomia and mucositis is anticipated in all irradiated patients.^(1,2,3) Application of NET, a known pain-reducing and healing therapy,^(4,5,6) appears to have provided the patient with almost complete relief.

Several patients have been seen at the VA Medical Center for NET treatment for post-radiation dryness, with equally good results. The success of this program warrants consideration for further study. It is felt that future research will uphold the efficacy of this treatment modality.

REFERENCES

1. Dreizen, S.; Daly, T.E.; Drane, J.B.; Brown, L.R.; Oral Complications of Cancer Radiation, *Postgrad Med* 61(2):85-92, 1977.
2. Regezi, J.A.; Courtney, R.M.; Kerr, D.A.; Dental Management of Patients Irradiated for Oral Cancer, *Cancer* 38(2):994-1000, 1976.
3. Shannon, I.L.; Trodahl, J.D.; Starcke, E.N.; Remineralization of Enamel by a Saliva Substitute Designed for Use by Irradiated Patients, *Cancer* 41(5):1746-1750, 1978.
4. Bauer, W.; Neuroelectric Medicine, *J Bioel* 2(2&3):159-180, 1983.
5. Ullis, K.C.; Transcript of an Alpha-Stim 2000 Training Program, *Internat Electrother Inst, Sydney, Australia, Aug 1983*.
6. Newland, A.L.; *Electro-Medical Therapeutics, a Guide to Its Clinical Application*, Century Medical Distributors, Inc., 1977.